

Dermatofibrosarcoma Protuberans A Rare Case Report

Ashish Agarwal¹, Rajkishore Singh², Kulwant Singh¹

Department Of Surgery, People's College Of Medical Sciences & Research Centre, Bhopal, 462037 (M.P.)¹

Department Of Surgery, Government Medical College, Rajnandgaon, Chattisgarh, India².

Abstract: Dermatofibrosarcoma is a rare, slow-growing and fibrohistocytic neoplasm. It is locally aggressive tumor and potential for distant metastasis is low. Its nature is intermediate to low-grade malignancy. It is commonly seen on the trunk followed by the proximal extremities and the head and neck. We came across one such case who presented with 40yrs of age with swelling over supra umbilical midline since 23yrs, gradually increased in size, not associated with pain. No other significant complaints were noted. Excision of tumor done under General Anesthesia. Histopathology section features are suggestive of Dermatofibrosarcoma of abdominal wall. Dermatofibrosarcoma protuberans is a cutaneous malignancy that arises from the dermis and invades deeper tissue (eg, fat, fascia, muscle, bone). Incomplete removal of these neoplastic cells results in a high local recurrence rate.

Keywords: Dermatofibrosarcoma protuberance, fibrohistocytic neoplasm, slow-growing, malignancy.

I. Introduction

Dermatofibrosarcoma protuberans (DFSP) is a very rare tumor. It is a rare neoplasm of the dermis layer of the skin, and is classified as a sarcoma. There is only about one case per million per year. DFSP is a fibrosarcoma, more precisely a cutaneous soft tissue sarcoma¹. Dermatofibrosarcoma protuberans is best considered a less malignant, but locally invasive form of malignant fibrous histiocytoma, will recur if it is not widely excised, but histologically typically having a high mitotic rate. It occurs on the trunk as a progressively enlarging smooth, bulbous, lobulated mass, often with ulceration of the overlying skin². The lesion presents as a nodular, cutaneous mass that shows slow and persistent growth. Satellite lesions may be found in patients with larger tumors. Standard treatment of DFSPs is wide local excision, with expected local recurrence rate of <10%³.

II. Case Report

A 40yrs old male patient, presented with swelling over supra umbilical midline region since 23yrs, which was gradually increased in size and not associated with pain, also there was no loss of weight and appetite. No other significant complaints were noted. This male patient from lower socio economic status was on antihypertensive treatment since 10 years.

On clinical examination a spherical swelling of size 7cm x 5 cm, noted at the epigastric region which was firm, mobile, non-tender with mild raised in temperature. Overlying skin was thinned out but free & exhibited brownish pigmentation and surface smooth with edges are well defined. Figure 1 showing the external appearance of the growth (Preoperative).

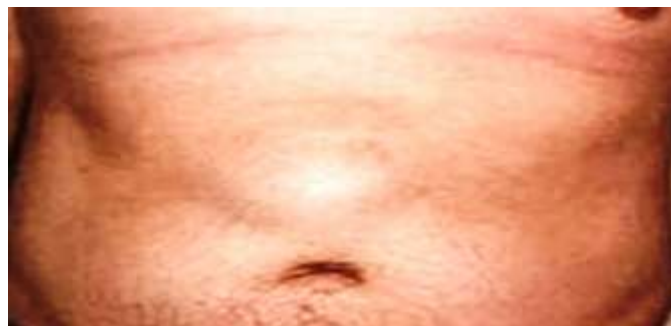

Fig1: Preoperative.

His routine investigations were within normal range. All blood serology reports were negative. Ultrasonography of the swelling suggestive of AV malformation. CECT of abdomen suggestive of Desmoid tumour. Fine needle aspiration cytology findings were inconclusive. Figure 2 showing the CECT appearance of the growth

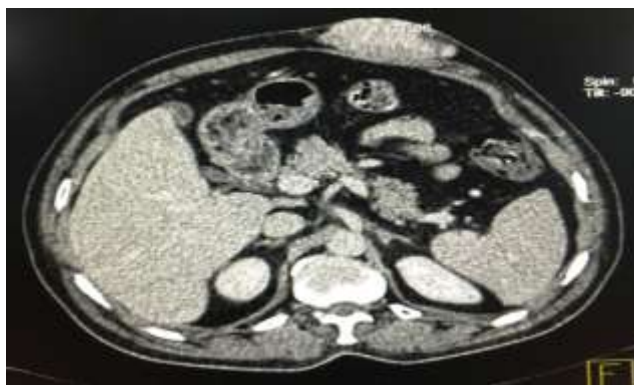

Fig 2 : CECT

After all the needful investigations patient was taken for surgery. Informed consent, including risk, benefit and alternatives given to the patient and family & documented. An upper abdomen transverse incision taken to excise the growth completely. Recovery was uneventful and patient is on regular follow up with us. Figure 3 showing the healing wound after one month. Specimen send revealed Dermatofibrosarcoma protuberans on histopathological examination (HPE). Figure 4 showing HPE of the specimen.

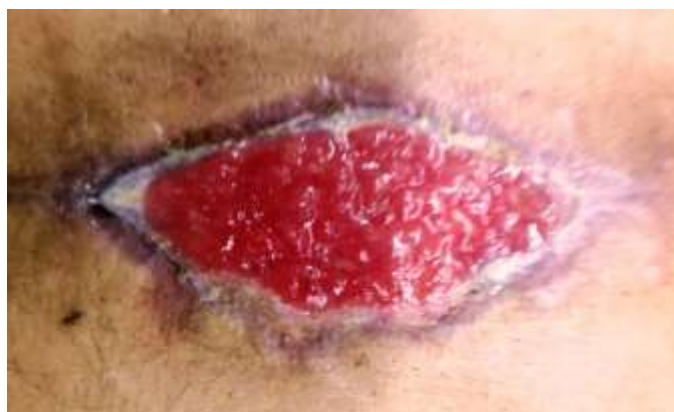

Fig 3 : Post op 1 (M)

HISTOPATHOLOGY

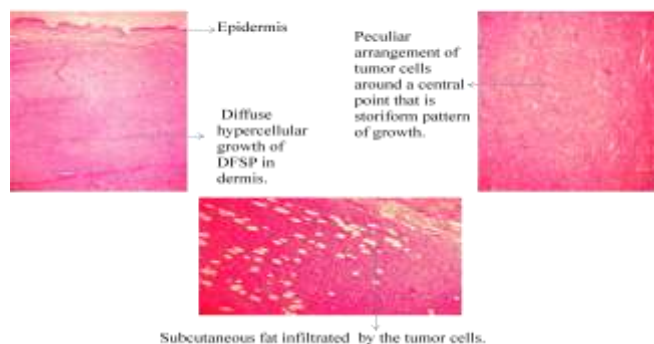


Fig 4 : HPE

III. Discussion

Dermatofibrosarcoma Protuberans, which accounts for approximately 7–15% of soft tissue sarcomas, usually presents as an elevated, firm, solitary, slowly growing, painless mass. Metastases are uncommon and an excellent outcome is achieved if histologically clear margins are obtained following local excision⁴. So DFSP can be summed as follows.

1. Low-grade malignant soft tissue tumor arising from the dermis.
2. Painless violet-red nodule that is present for several years.
3. May be associated with ulceration.
4. Treatment includes wide resection with possible external beam radiation⁵. Most authors advocate surgical excision with a minimal margin of 2 to 3 cm of surrounding skin, including the underlying fascia, without elective lymph node dissection.⁶

IV. Conclusion

DFSP is a low-grade cutaneous sarcoma with aggressive local behavior and low metastatic potential. DFSP classically presents as a plaque on the trunk and, less frequently, on the extremities, but it may occur anywhere. Treatment options for DFSP include wide local excision and Mohs micrographic surgery.

Acknowledgement

The authors acknowledge the assistance of Akash Jain for help in the preparation of this article.

References

- [1]. Wikipedia. https://en.wikipedia.org/wiki/Dermatofibrosarcoma_protuberans .
- [2]. Key Topics in General Surgery, Second Edition , *C.R. Lattimer* , Soft tissue swelling , 2002, 356 .
- [3]. Schwartz's Principles of Surgery, Ninth Edition, F. Charles Brunicaardi, The Skin and Subcutaneous Tissue 2010 , Chapter 16.
- [4]. Textbook of surgery, Joe J. Tjandra , Third edition , 2006, 341.
- [5]. Handbook of Plastic Surgery , Steven E.Greer, M.D. 2006, 476.
- [6]. Fiore M, Miceli R, Mussi C, et al. Dermatofibrosarcoma protuberans treated at a single institution: a surgical disease with a high cure rate. *J Clin Oncol* 2005;23(30):7669.